ԵՐԵՎԱՆԻ «ՀԱՅԲՈՒՍԱԿ» ՀԱՄԱԼՍԱՐԱՆԻ ԳԻՏԱԿԱՆ ԵՎ ԳԻՏԱՄԵԹՈԴԱԿԱՆ ՀԱՆԴԵՍ
YEREVAN "HAYBUSAK" UNIVERSITY SCIENTIFIC AND SCIENTIFIC-METHODOLOGICAL JOURNAL

ԲԺՇԿԱԳԻՏՈՒԹՅՈՒՆ ԲՆԱԿԱՆ ԳԻՏՈՒԹՅՈՒՆՆԵՐ

3

MEDICINE NATURAL SCIENCES

2022

ԵՐԵՎԱՆԻ «ՀԱՅԲՈՒՍԱԿ» ՀԱՄԱԼՍԱՐԱՆԻ ԳԻՏԱԿԱՆ ԵՎ ԳԻՏԱՄԵԹՈԴԱԿԱՆ ՀԱՆԴԵՍ
YEREVAN "HAYBUSAK" UNIVERSITY SCIENTIFIC AND SCIENTIFIC-METHODOLOGICAL JOURNAL

ԵՐԵՎԱՆԻ «ՀԱՅԲՈՒՍԱԿ» ՀԱՄԱԼՍԱՐԱՆ

YEREVAN "HAYBUSAK" UNIVERSITY

ԲԺՇԿԱԳԻՏՈՒԹՅՈՒՆ
ԲՆԱԿԱՆ ԳԻՏՈՒԹՅՈՒՆՆԵՐ

MEDICINE
NATURAL SCIENCES

3

ԵՐԵՎԱՆ - YEREVAN - **2022**

SONO CONTROL ARM ACCORDING TO PROF BABAYAN WHEN USING THE MIBRAR METHOD

Arsen Babayan

Dr. Med. sci, Prof, «Spine and Joint Center», Munich, Germany

Abstract: *The image resolution of today's sonography has gained in visual, image contrasts, and depth of the visible tissue structures so that the range of applications for sonography has significantly expanded in the medical fields. Particularly in orthopedics, accident surgery, neurosurgery, intensive neurosurgery, and regional anesthesia, the optical requirements and the increased use of sonography are to be found here.*

Sonography can represent the most diverse tissue structures much more accurately and more securely than the commonly used methods such as radiography, MRI, and CT.

Most imaging methods provide static images. Using ultrasound, you can create "moving images" for movement sequences for the functional assessment of tissues and structures. Movable images are also possible for video recordings and also for visual inspection of the overall movement of the instruments during the course of the operation. Thus, a dynamic examination and visual inspection with a representation of structures of all tissues in different body parts in real-time is possible.

Nowadays, sonography is used not only for diagnosis but also for intra-operative therapeutic use to control the operation, i.e. to perform surgery under ultrasound.

During the surgical procedure - particularly in the micro-therapeutic field - the image presentation of the sonography is particularly important for the safety orientation and the ongoing control of the surgical instruments used.

Keywords: *Sono Control Arm, micro invasive, regenerative reconstruction, no cut, without narcosis*

INTRODUCTION

In the reverse sense, this means that without the imaging of the sonography, many surgical procedures - particularly in the micro-therapeutic area - would not be possible or very severely restricted.

With the today's practice of freehand realized Sonography-intervention or Sonography-control, exist the following disadvantages:

First, a surgeon's hand is always occupied with the ultrasonic head probe and permanently busy with the post-correction to create and maintain a qualified, sonographic image. This is done with simultaneous, constant monitoring of the monitor on which the sonographic images are displayed.

Secondly, the continuous visual inspection (in the sound width of micro-dimensions) of the manually guided ultrasonic head means a tremendous strain on the surgeon who must simultaneously focus on two instruments: the ultrasonic head and the surgical instrument. Such uncertainties and complex processes have hitherto prevented the intra-operative use of the ultrasound in difficult interventions, and the clear advantages of the ultrasound visualization that is

superior today are obviously not used for intra-operative interventions.

From these years of experience, the Sono Control Arm has been developed from me with a special holder for the ultrasound head, which is highly mobile for the most varied areas of operation in the OP in flowing, easy movements and at the same time with maximum precision in every position. Furthermore, with a handle it is securely fixable in order not to lose the sound layer of the ultrasound imaging.

According to the present state of the art, such interventions are carried out using a permanent x-ray control, which can have a harmful radiation exposure for the patient. The X-ray-based visualization also has the great disadvantage of the not possible representation of numerous tissues and organs (nerves, vessels, musculature, tendons, ligaments, volume, and parenchymatous organs, cartilage). Which is the prerequisite for an accurate and safe execution of an intervention.

METHODS

Due to the optimal use of the sonography by the targeted use of the Sono Control Arm, the micro-therapeutic MIBRAR method can perform safely and successfully all joint or spinal surgery operations without having to open the body and still with complete visual inspection. This technical advancement is the prerequisite for performing an ankle or spinal surgery with the aid of the MIBRAR method without the usual anesthesia and the usual operating expenditure with hospital stay. The surgeon thus has both hands free and is relieved from the internal tension, which entails constant manual guidance and visual inspection of the ultrasound head. Instead, the operator can concentrate all his attention on the operation and the instrumental use.

A further advantage of the Sono Control Arm is the fundamental safety of maintaining a desired position and imaging of the ultrasound head - especially during surgery, which can hardly be ensured by handholding in this exact position over an extended period. This method of operation and use of the Sono Control Arm also allows much more complicated surgical procedures to be performed than hitherto possible.

Thanks to this Sono Control Arm device, the valuable and qualified imaging of the ultrasound can be used optimally intra-operatively in order to perform much more precise and safe interventions, whereby the secure ultrasound head guidance is achievable in under 1 mm dimensions.

The sonography, applied by the Sono-Control arm safely, is a very crucial aid to realize under precise visual inspection

- the planning of the operations accesses and
- the performance of the operations or
- the introduction of an endoscope
- and the entire operating sequence without the risk of uncontrollably violating important tissue structures or organs.

RESULTS

The safe imaging of sonography using the Sono Control Arm and the MIBRAR method has many advantages:

- There is no radiation exposure to the patient due to intra-operative imaging instruments such as image transducer / X-ray / C-arm.
- The micro-invasive procedure according to the MIBRAR method is enormously timesaving, so that the overall procedure is less stressful for the patient.
- The time saving with the use of the micro-invasive MIBRAR method and the help of modern sonography makes it possible to carry out more complex and complex procedures in the joint or spinal area.

These interventions are carried out as efficiently and gently as possible in a wide range of areas, such as e.g.

- for intra-spinal interventions in the spinal canal,
- for intervertebral discs
- or in micro-invasive interventions on joints, e.g. the micro-invasive arthroscopy. This innovation revolutionizes today's existing worldwide surgery.

Clinical case description No. 6

Male / 49 years old

Anamnesis:

The patient was operated due to the knee osteoarthritis (grade IV) and meniscal tears (abrasion arthroplasty + micro-perforations) in an attempt to rebuild a cartilage. In the two and a half months after the surgery the situation worsened significantly. A progressive knee swelling and knee pain was identified. The patient

was not able to walk independently, only with two underarm crutches. The knee was absolutely immobilized. An osteonecrosis has developed.

Diagnosis:

Left knee joint in a postoperative condition; arthritis (grade IV); bone edema and osteonecrosis of a medial femoral condyle; meniscus degeneration.

Surgical report 29.01.2016:

Intraosseous, intrameniscal and intraarticular transplantation of stem cells and growth factors concentrate via MIBRAR® method received that was created from abdominal fatty tissue by LIPOGEMS technology, also autologous concentrate from venous blood via CGF technology into the medial femoral condyle, medial meniscus and joint gap of the left knee joint.

Images description:

MIBRAR® surgery on the left knee joint.

The images 5 and 7 dated 12.01.2016

MRI images on different levels correspond to the preoperative status and show osteonecrosis, bone edema, meniscus degeneration and massive fluid retention.

Images 6 and 8 dated 02.06.2017

MRI images on different levels correspond to the postoperative status in 1,5 years after the MIBRAR® surgery. Osteonecrosis and bone edema can no longer be seen, a complete regeneration of meniscus and cartilage layer have been noted.

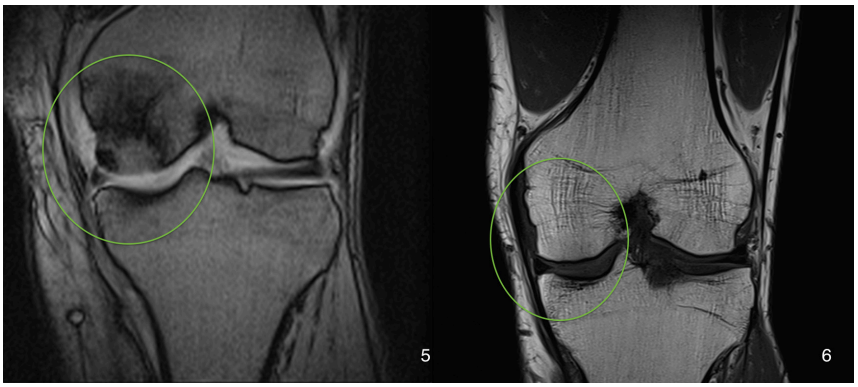

Surgery result:

All the symptoms disappeared within 4 weeks after the surgery, the patient can move freely without crutches. Within 8 weeks after the surgery, the patient was able to do a competitive sport without any problems, up to the present day the patient is free of complaints.

Clinical case description No. 7

Male / 56 years old

Anamnesis:

The patient complains on girdle pains in medial area of the right knee joint during motion and bending. After applying pressure to the knee joint the patient experiences knee swelling. Due to pain the patient wakes up at night. During the last 2 months the complaints have worsened significantly.

Diagnosis:

Posterior horn medial meniscus tear
Patellofemoral and tibiofemorale cartilage abrasion, osteoarthritis (grade I-II)

Surgical report dated 03.05.2017:

Intrameniscal and intraarticular transplantation of stem cell and growth factors concentrate by MIBRAR® method received and created from abdominal fatty tissue by LIPOGEMS technology, also autologous concentrate from venous blood via CGF technology into the medial meniscus and joint gap of the right knee joint

Images description:

MIBRAR® surgery on the right knee joint
Images 3 dated 31.08.2016
MRI images on different levels correspond to the preoperative status; they show posterior horn medial meniscus tear and cartilage abrasion clearly.

Images 4 dated 30.05.2017

MRI images on different levels correspond to the postoperative status in 4 weeks after the MIBRAR® surgery. Meniscus particles have grown together; a regeneration of cartilage layer can be noted.

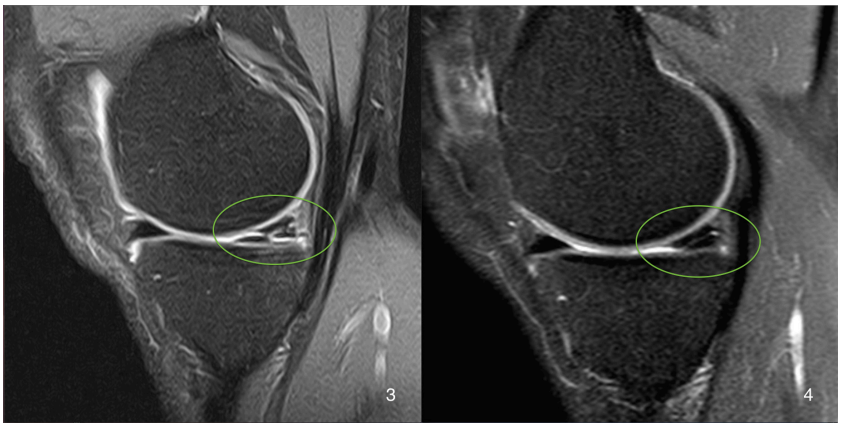

Surgery result:

All the symptoms disappeared within 1 week after surgery, the patient can move freely. Within 3 weeks after the surgery patient was able do a sport without any problem up to the present day.

АРСЕН БАБАЯН. SONO CONTROL ARM ПО ПРОФ. БАБАЯНУ ПРИ ИСПОЛЬЗОВАНИИ МЕТОДА МИБРАР. *Разрешение изображений современной сонографии улучшилось благодаря визуальным контрастам изображения и глубине видимых структур тканей, так что диапазон применения сонографии в медицинских областях значительно расширился. В частности, в ортопедии, травматологической хирургии, нейрохирургии, интенсивной нейрохирургии и регионарной анестезии здесь можно найти оптические требования и более широкое использование сонографии. Сонография может отображать самые разнообразные структуры тканей гораздо точнее и надежнее, чем широко используемые методы, такие как рентгенография, МРТ и КТ. Большинство методов визуализации предоставляют статические изображения. Используя ультразвук, вы можете создавать «движущиеся изображения» для последовательностей движений для функциональной оценки тканей и структур. Подвижные изображения также возможны для видеозаписи, а также для визуального наблюдения за общим движением инструментов в ходе операции. Таким образом, возможен динамический осмотр и визуальный осмотр с отображением структур всех тканей в разных частях тела в режиме реального времени.*

В настоящее время сонографию применяют не только для диагностики, но и для интраоперационного терапевтического применения для контроля операции, т.е. для выполнения операции под ультразвуковым контролем. Во время хирургической процедуры, особенно в микротерапевтической области, представление изображения на сонографии особенно важно для ориентации на безопасность и постоянного контроля над используемыми хирургическими инструментами.

ԱՐՍԵՆ ԲԱԲԱՅԱՆ: SONO CONTROL ARM - Ը MIBRAR ՄԵԹՈԴԻ ԿԻՐԱՌՄԱՆ ԴԵՊՔՈՒՄ: *Ներկա սոնոգրաֆիկ պատկերների բարձր լուծողունակությունը թույլ է տալիս հյուսվածքների պատկերների տեսողական զննում, որը զգալիորեն ընդլայնել է սոնոգրաֆիայի կիրառման շրջանակները բժշկության մեջ, հատկապես օրթոպեդիայի, դժբախտ պատահարների վիրաբուժության, նյարդավիրաբուժության, ինտենսիվ նյարդավիրաբուժության և ռեգիոնալ անզգայացման ոլորտներում: Սոնոգրաֆիան կարող է շատ ավելի ճշգրիտ և անվտանգ ներկայացնել հյուսվածքների ամենափարբեր կառուցվածքները, քան սովորաբար օգտագործվող ռենտգենյան, ՄՌՏ և ԿՏ մեթոդները: Ներկայումս սոնոգրաֆիան օգտագործվում է ոչ միայն ախտորոշման, այլ նաև ներվիրահատական նպատակներով՝ ուլտրաձայնային վիրահատություն և շարունակական հսկողության իրականացնելու համար:*

Ներկայումս սոնոգրաֆիան օգտագործվում է ոչ միայն ախտորոշման, այլ նաև ներվիրահատական նպատակներով՝ վիրահատությունը վերահսկելու համար, այսինքն. Վիրահատությունը կատարել ուլտրաձայնային հսկողությամբ. Վիրահատության ընթացքում, հատկապես միկրոթերապիայի ոլորտում, օգտագործվող վիրաբուժական գործիքների նկատմամբ մշտական հսկողության համար